

Dendritic Cells and Pattern of Cytokines in Paracoccidioidomycosis Skin Lesions

Carla Pagliari, Ph.D., and Mírian N. Sotto, M.D., Ph.D.

We demonstrated and quantified by immunohistochemistry epidermal Langerhans cells, CD34+ dermal dendrocytes (DDs), and cells expressing TNF α , interferon- γ (IFN γ), IL-5, and IL-10 in skin lesions of paracoccidioidomycosis (PCM). Sixty-one biopsies were classified in three groups according to the pattern of tissue response: Group 1, well-organized granuloma; Group 2, poorly organized granuloma; and Group 3, both kinds of granuloma. Langerhans cells had short and irregular dendrites in all groups and were decreased in number in Groups 1 and 2. CD34+ DDs did not differ in number from the control group. Group 1 was characterized by many cells expressing IFN γ . Groups 2 and 3 exhibited large numbers of cells expressing IL-5 and IL-10. The data obtained suggest that well-organized granulomas reflect a better cellular immune response, and the large number of cells expressing IL-5 and IL-10 in Group 2 indicate an ineffective response in PCM skin lesions. Both kinds of granuloma in the same cutaneous lesion probably represent an intermediate response between the anergic and hyperergic poles. Group 3 also showed higher numbers of cells expressing TNF α when compared with the control group. Some cells expressing TNF α were dendritic and localized around the granuloma similar to the factor XIIIa+ DD localization that we previously described.

Key Words: Skin—Dendritic cells—Cytokines—Paracoccidioidomycosis.

Paracoccidioidomycosis (PCM) is a human systemic mycosis caused by the dimorphic fungus *Paracoccidioides brasiliensis*. It is confined to Latin America, with endemic areas in Brazil, Argentina, Colombia, and Venezuela. Primary lesions are thought to occur in the lungs. From these lesions, the fungi can disseminate via the bloodstream or lymphatics to any organ of the host, and the skin is involved in approximately 50% of cases (1). Cutaneous lesions constitute an important clinical element of the diagnosis because they represent an exteriorization of the disease.

The lesions of PCM are characterized by a granulomatous inflammatory response with formation of epithelioid granulomas with giant cells. The hyperergic pole of PCM is characterized by compact epithelioid granulomas, and the anergic pole is represented by a loose and parasite-rich granulomatous response. The skin lesions reflect a reduction in the number of Langerhans cells (LCs), resulting in an impairment in the local processing of antigens (2).

Dermal dendrocytes (DDs) constitute a group of dendritic cells with an antigen-presenting cell phenotype (3). These cells were identified by the expression of factor XIIIa (FXIIIa), a protransglutaminase involved in hemostasis, and classified as type I dendrocytes. Another dendritic cell described within the human dermis and identified by the expression of the human progenitor cell antigen CD34 was classified as type II (4–7).

Brandão et al. (8) detected more FXIIIa+ DDs in PCM oral lesions, suggesting that these cells might be related to granuloma formation. We recently described the presence of fungi inside FXIIIa+ DDs (9). These cells were hypertrophic and increased in number and were localized in the superficial and reticular dermis. The precise role of CD34+ DDs remains to be established. It seems that these cells might differentiate toward more differentiated cells such as CD1a+ LCs or FXIIIa+ DDs (10–12).

The cellular immune response mediated by CD4+ T cells producing a T helper (Th) 1 pattern of cytokines (interferon [IFN] and IL-2) represents the main resis-

From the Departamento de Patologia (C.P.) e Dermatologia (M.N.S.), Faculdade de Medicina da Universidade de São Paulo, São Paulo, Brazil.

Address correspondence and reprint requests to Mírian N. Sotto, M.D., Ph.D., Av. Dr. Arnaldo, 455 sala 1118, Cep 01246-903, Faculdade de Medicina da Universidade de São Paulo, São Paulo, SP, Brazil. E-mail: mnsotto@ajato.com.br.

This work was supported by Fundação de Amparo à Pesquisa do Estado de São Paulo (FAPESP) grant 99/05086-1.

tance mechanism against *P. brasiliensis*. Susceptibility is associated with the Th2 pattern of cytokine production (IL-4, IL-5, IL-6, and IL-10) (13–17). Tumor necrosis factor is a potent stimulant of leukocyte function and granuloma formation. In patients with chronic PCM, high serum levels of IL-10 and TNF α and low levels of IFN γ were related to progression of the disease (18,19).

In the current study, we investigated the correlation between skin dendritic cells (LCs and CD34+ DDs), the morphologic characteristics of the granulomatous response, and the expression of cytokines of the Th1 and Th2 patterns in the skin lesions of PCM.

MATERIALS AND METHODS

Sixty-one skin biopsies from patients with a clinical diagnosis of PCM confirmed by direct examination or fungal culture were selected from the files of the Dermatopathology Laboratory of the Department of Dermatology of the University of São Paulo Medical School according to the amount of tissue available to perform all the proposed immunohistochemical techniques. All specimens had been fixed in neutral buffered formalin and embedded in paraffin. They were classified according to tissue response (20,21) into well-organized granuloma (Group 1), poorly organized granuloma (Group 2), and both kinds of granuloma (Group 3). Ten biopsies from normal skin were used as controls.

Immunohistochemistry

Four-micrometer sections were dewaxed in xylene and hydrated through a graded series of ethanol. Endogenous peroxidase was blocked with 3% hydrogen peroxide, and preincubation with trypsin (Sigma Chemical Company, St. Louis, MO) in 0.01 M of PBS, pH 7.4, was performed to enhance antigen exposure when necessary. The following primary antibodies were applied, and sections were incubated overnight at 4°C: rabbit anti-*P. brasiliensis* (kindly supplied by Prof. Carlos Lacaz, Tropical Medicine Institute, São Paulo Medical School) diluted 1:1,000, mouse anti-CD1a (Immunotech, Marseille, France), mouse anti-CD34 (Novocastra, Newcastle, UK) diluted 1:50, rabbit anti-TNF α diluted 1:100, goat anti-IFN γ diluted 1:250, and rabbit anti-IL-5 (Genzyme, Cambridge, MA) and mouse anti-IL-10 (R&D Systems, Minneapolis, MN) used at 1:50 and 1:10 dilutions, respectively. Biotinylated antirabbit and antimouse antibody was used at a dilution of 1:1,000 for 30 minutes at 37°C (DAKO Corporation, Carpinteria, CA). For the detection of IFN γ , biotinylated antigoat antibody was used at a dilution of 1:800 (DAKO Corporation). Peroxidase-labeled streptavidin-biotin complex (SABC; DAKO Corporation) was applied for 30 minutes at 37°C at a dilution of 1:1,000. Langerhans cells and cells expressing IL-5

were better visualized by using the catalyzed signal amplification (CSA) system (DAKO Corporation) based on the peroxidase-catalyzed deposition of a biotinylated phenolic compound followed by a secondary reaction with streptavidin peroxidase (22). As a chromogen, we used 3,3 diamino-benzidine tetrahydrochloride (Sigma Chemical Company), and the slides were counterstained with Harris hematoxylin.

Specimens of PCM lesions, normal skin, Kaposi sarcoma, and reactive lymph node were used as positive controls for the immunohistochemical detection of *P. brasiliensis* antigens, LCs, CD34+ DDs, and cells expressing cytokines, respectively. The negative controls were obtained by omitting the primary antibodies for each reaction, which were replaced by PBS.

Quantitative Analysis

Cells were quantified by counting the number of immunolabeled cells in 15 randomized high-power fields for each specimen with a $\times 10$ ocular lens with a square grid and a $\times 40$ objective. Epidermal LCs were evaluated by determining the epidermal area fraction with positivity for CD1a (23).

Statistical Analysis

The number of positive cells was statistically analyzed by the Graph Pad Prism version 3.00 for Windows (GraphPad Software, San Diego, CA) using a Kruskal-Wallis test with the level of significance set at 95%.

RESULTS

Histopathologic Analysis

The histopathologic study revealed 22 biopsies characterized by well-organized granuloma (Group 1) (Fig. 1A), 20 characterized by poorly organized granuloma (Group 2) (see Fig. 1B), and 19 with both kinds of granuloma in the same biopsy (Group 3). The most frequent epidermal changes were hyperkeratosis, parakeratosis, acanthosis, and pseudocarcinomatous hyperplasia. Epidermal microabscesses were observed in 60% of the biopsies, some of them with fungi among the polymorphonuclear cells. Besides the granulomatous reaction, the dermis presented a perivascular inflammatory infiltrate composed predominantly of lymphocytes, plasma cells, and macrophages. Neutrophils were frequently observed, and eosinophils were present in almost 20% of the biopsies. Dermal necrosis and fibrosis were rarely seen. Vascular alterations were characterized by swelling of endothelial cells. Fungi were seen in the cytoplasm of macrophages and giant cells in all sections and were better demonstrated by anti-*P. brasiliensis* antibody.

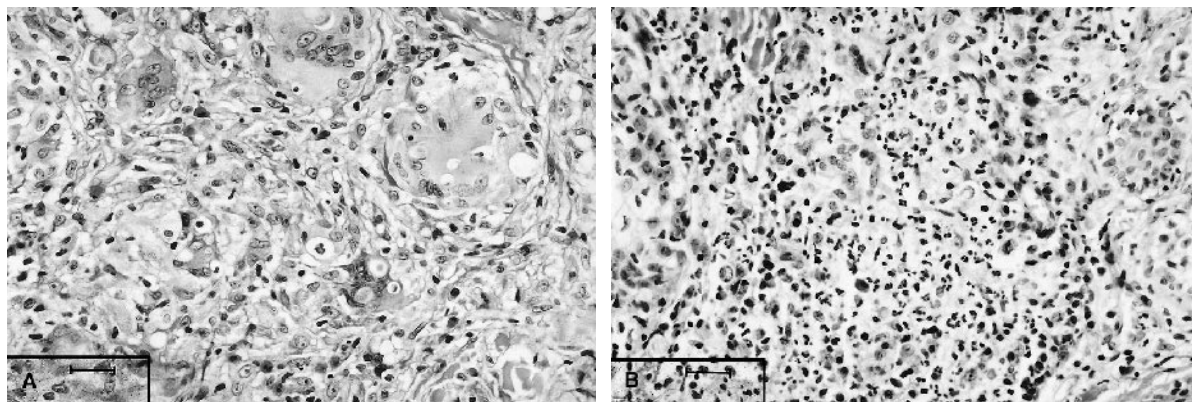


FIG. 1. Patterns of granulomatous tissue reaction in paracoccidioidomycosis. (A) Well-organized granuloma characterized by compact clusters of epithelioid cells, giant cells, and mononuclear cells in a peripheral halo around the granulomas. (B) Poorly organized granuloma characterized by loose aggregates of epithelioid cells intermingled with mononuclear cells (hematoxylin–eosin).

Distribution of Dendritic Cells

Langerhans cells were distributed throughout the epidermis with short and irregular dendrites in Groups 1 and 2 (Fig. 2A). Dendrites were long and numerous in the control group (Fig. 2B). Quantitative analysis showed a statistically significant decrease in the number of cells immunolabeled with the anti-CD1a antibody in Groups 1 and 2 when compared with the control group ($P < 0.001$) (Fig. 3). CD34+ DDs were spindle shaped and distributed in the dermis, especially in the adventitia of sebaceous and sudoriparous glands. In the control group, these cells had the same characteristics as in PCM. Statistical analysis did not show differences between the groups in the number of CD34+ DDs.

Distribution of the Cytokines in the Skin Lesions

Cells expressing TNF α were distributed throughout the dermis in the inflammatory infiltrate. Interestingly,

some positive dendritic cells were localized around the granulomas similar to the distribution of FXIIIa+ DDs that we previously described (9). The quantitative analysis revealed a statistically significant increase in the number of cells expressing TNF α in Group 3 when compared with the control group (Fig. 4A). Cells expressing IFN γ were detected in the dermal inflammatory infiltrate of the three PCM groups. Group 1 was characterized by more of these cells when compared with Group 2 ($P < 0.001$) and the control group (Fig. 4B). Interleukin-5–stained lymphocytes were distributed in the dermal inflammatory infiltrate. A statistically significant increased number of positive cells were detected in Groups 2 and 3 when compared with the control group (Fig. 4C). Lymphocytes and some mast cells immunolabeled with the anti-IL-10 antibody were distributed in the dermis among the inflammatory infiltrate. More of these cells were present in Groups 2 and 3 when compared with the control group ($P < 0.01$) (Fig. 4D). On the whole, the

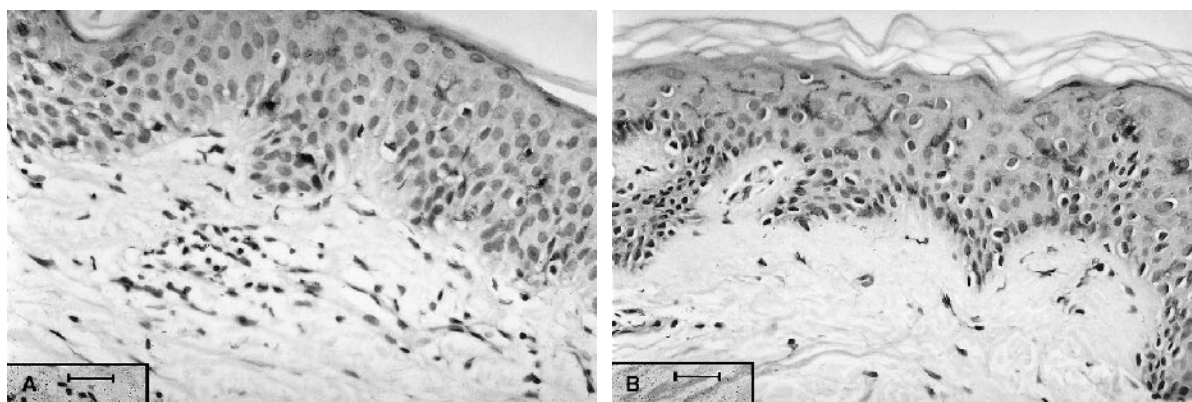


FIG. 2. Epidermal Langerhans cells immunostained by anti-CD1a antibody. (A) Paracoccidioidomycosis lesion with well-organized granuloma showing epidermal Langerhans cells with short and irregular dendrites. (B) Langerhans cells distributed throughout the epidermis with long and numerous dendrites in the control group (streptavidin-biotin complex immunohistochemical technique).

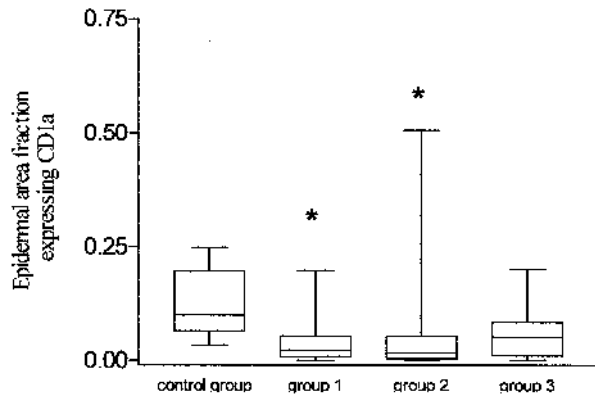


FIG. 3. Distribution of CD1a+ epidermal area fraction (Langerhans cells) in paracoccidioidomycosis lesions according to the type of granulomatous reaction and in the control group. Horizontal lines represent the median values, boxes represent the 25th to 75th percentiles, and whiskers show the highest and lowest values. *Statistically different from the control group (Kruskal-Wallis test).

morphology of cells expressing TNF α , IFN γ , IL-5, and IL-10 present in the control group was similar to that found in the PCM groups.

DISCUSSION

Cutaneous involvement in PCM is frequent. The infection begins in the lungs and reaches the skin via bloodstream dissemination of *P. brasiliensis*.

The specific cell populations that are involved in disease control in different organs have been identified so as to better understand the organ-specific immune response (24). The skin has many different immunologically active cells, and the most important are probably the dendritic cells (25).

Although it is possible to identify two well-defined poles in PCM in experimental animal models, there are a number of immune and histopathologic responses in human beings. The clinical form reflects a particular phase in a dynamic and polymorphic disease (26).

The reduction of LCs in diverse pathologic processes has been described (27–29). In our work, epidermal LCs (CD1a+) showed degenerative alterations and a reduced number in Groups 1 and 2 when compared with the control group ($P < 0.01$). This numeric reduction could be a result of factors produced by *P. brasiliensis*, or these cells may have migrated to the dermis, resulting in an immunophenotypic alteration in membrane expression of CD1a. Sandoval et al. (30) did not detect *P. brasiliensis* antigens in the cytoplasm of LCs, suggesting that they would not be capable of presenting fungal antigens efficiently. On the other hand, we could detect some yeast cells in the cytoplasm of FXIIIa+ DDs by double immunostaining (9). It was suggested that DDs might represent a possible dermal precursor of epidermal LCs (11). We

observed that Group 3 did not present numeric depletion of LCs and previously observed that FXIIIa+ DDs appeared hypertrophied and hyperplastic in this group (9). We suppose that FXIIIa+ DDs could be a reservoir for the repopulation of epidermal LCs in this PCM group.

CD34 antigen is present in human hematopoietic progenitor cells from bone marrow. Within the dermis, CD34 is expressed by endothelial cells, dendritic cells, and spindle-shaped cells around adnexal structures (31). Few works demonstrate the function of CD34+ DDs as well as their relation with other cutaneous dendritic cells. They do not express CD1a or S100 protein, are more frequent in the reticular and deep dermis, and only 2% express HLA-DR under normal conditions (10). It is suggested that these cells can differentiate into more specialized dendritic cells such as FXIIIa+ DDs or LCs after the stimulatory effects of TNF α and granulocyte macrophage colony-stimulating factor (GM-CSF) (10–12). We observed few CD34+ DDs in the superficial and reticular dermis, without differences between the groups. It was not possible to correlate this cell population with the other dendritic cells. Their role in skin tissue reaction to *P. brasiliensis* warrants further investigation.

Products from *P. brasiliensis* may stimulate macrophages to secrete TNF α , which is involved in granuloma development (16,21). We demonstrated the presence of dermal cells that expressed TNF α in the three groups of PCM. Some of these cells had a dendritic morphology and distribution in the periphery of granulomas similar to the distribution of FXIIIa+ DDs that we previously described (9). Group 3 showed the highest numbers of cells expressing TNF α and FXIIIa+ DDs, suggesting their participation as TNF α -producing cells following fungal stimulation.

Interferon- γ plays a pivotal role in host resistance against *P. brasiliensis* (17,32,33). Although we detected cells expressing IFN γ in the three PCM groups, Group 1 had more of these cells, correlating with a well-organized tissue response against *P. brasiliensis* with this cytokine.

Interleukin-5 is a Th2 type cytokine related to the maturation and differentiation of eosinophils (34,35). In experimental PCM, high levels of IL-5 and IL-10, eosinophilia, and low levels of IFN γ characterize the progressive disease in susceptible animals (32,36). We demonstrated more cells expressing IL-5 in Groups 2 and 3 similar to the results of cells expressing IL-10. These results suggested that poorly organized granulomas, which characterize Group 2, represent a worse response against *P. brasiliensis*.

It was interesting to observe that Group 3, the one with both kinds of granuloma formation, did not differ from Group 1 in the number of IFN γ -expressing cells. We could demonstrate that the number of FXIIIa+ DDs was increased in Group 3 of skin lesions (9) and so was the number of TNF α -expressing cells, some of them with

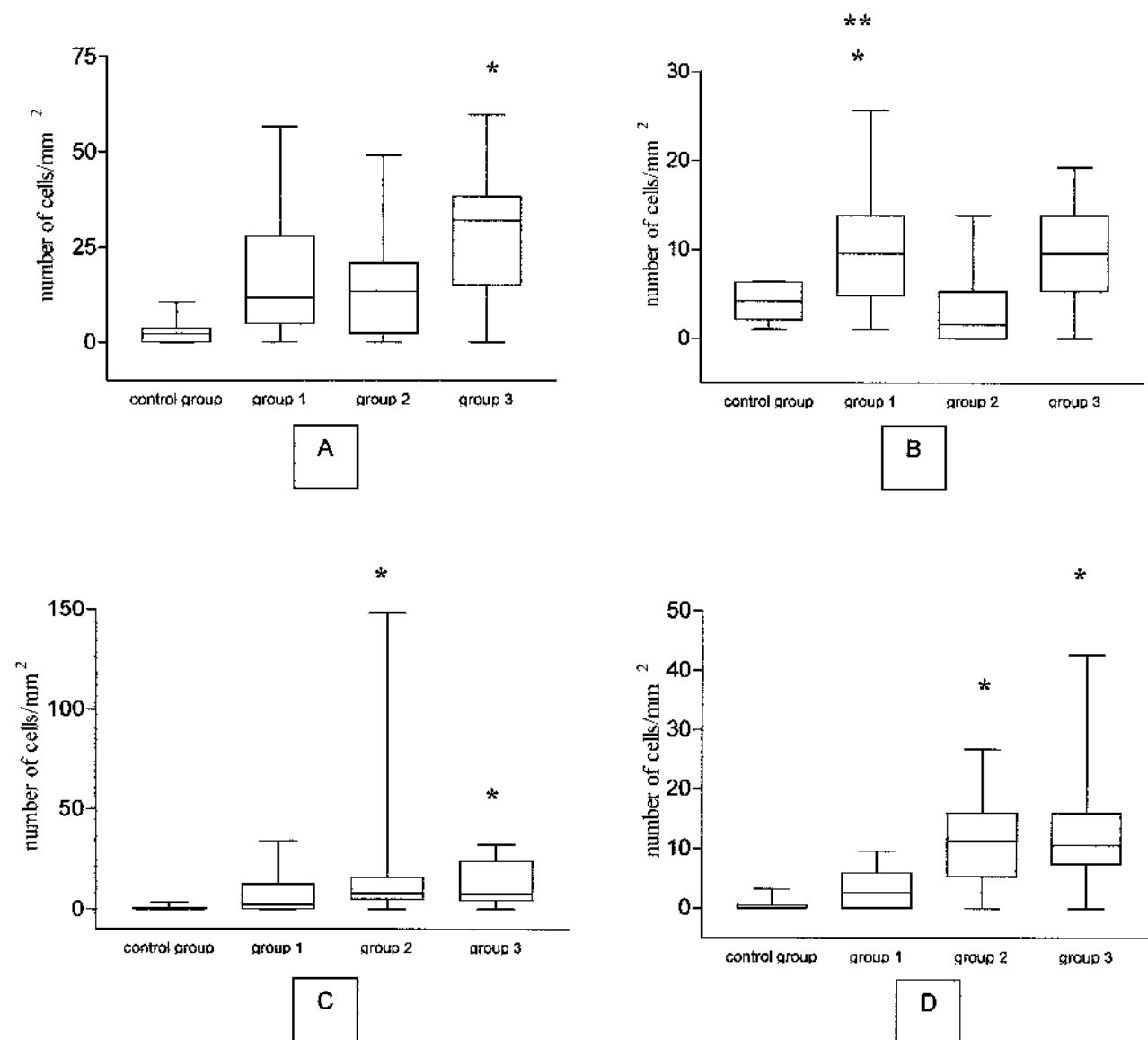


FIG 4. Distribution of the number of cytokine-expressing cells per square millimeter in paracoccidioidomycosis skin lesions according to the type of granulomatous reaction and control group. (A) Tumor necrosis factor- α -expressing cells. (B) Interferon- γ -expressing cells. (C) Interleukin-5-expressing cells. (D) Interleukin-10-expressing cells. Horizontal lines represent the median values, boxes represent the 25th to 75th percentiles, and whiskers show the highest and lowest values. *Statistically different from the control group (Kruskal-Wallis test). **Group 1 greater than Group 2 (Kruskal-Wallis test).

dendritic morphology. FXIIIa+ DDs have been related to Th1 type cytokine cutaneous processes (37). We suppose that these cells expressing TNF α in PCM skin lesions might be activated to improve the immune response against *P. brasiliensis*.

There are many factors that can regulate Th1/Th2 cell expression such as genetic background, the type of antigen-presenting cell interacting with T cells, and the cytokine microenvironment at the time of activation. Calich et al. (36) related the difference in the immune response to *P. brasiliensis* antigens to the interaction between the antigens and different populations of anti-

gen-presenting cells. Almeida and Lopes (38) studied dendritic cells in resistant and susceptible mice following inoculation with GP43 and demonstrated that the preferential activation of Th1 and Th2 responses, respectively, by those cells seems to be determined by the costimulatory microenvironment of cytokines in the early phases of infection. The presence of IFN γ would stimulate these cells to produce IL-12, inducing a Th1 response. On the other hand, IL-10, prostaglandin E, or IL-4 stimulates a Th2 response (39).

The presence of different populations of dendritic cells in the skin and their antigen-presenting capacity consti-

tute important factors in the immune response against *P. brasiliensis*. Understanding the correlation between these cells and cytokines could contribute to possible treatment targeting. The immunologic mechanisms that confer resistance to PCM are dependent on various factors, and dendritic cells seem to play a role.

Our results suggest the participation of LCs and FXIIIa+ DDs in the pathogenesis of the PCM cutaneous tissue response. These cells could act as antigen-presenting cells and/or fungal target cells. They would be related to the production and induction of the cytokines that modulate the immune response against the parasite.

The cutaneous tissue response in PCM correlates with the mechanisms that occur in other organs but with characteristic mechanisms that are related to its own immune system. □

REFERENCES

- Marques SA. Cutaneous lesions. In: Franco MF, Lacaz CS, Restrepo A, et al., eds. *Paracoccidioidomycosis*. Boca Raton: CRC Press, 1994:259–69.
- Gimenez MF, Tausk F, Gimenez MM, et al. Langerhans cells in paracoccidioidomycosis. *Arch Dermatol* 1987;123:479–81.
- Headington JT. The dermal dendrocyte. *Adv Dermatol* 1986;1:159–71.
- Cerio R, Griffiths CEM, Cooper KD, et al. Characterization of factor XIIIa positive dermal dendritic cells in normal and inflamed skin. *Br J Dermatol* 1989;121:421–31.
- Derrick EK, Barker JNW, Khan A, et al. The tissue distribution of factor XIIIa positive cells. *Histopathology* 1993;22:157–62.
- Nickoloff B. The human progenitor cell antigen (CD34) is localized on endothelial cells, dermal dendritic cells and perifollicular cells in formalin fixed normal skin on proliferating endothelial cells and stromal spindle-shaped cells in Kaposi's sarcoma. *Arch Dermatol* 1991;127:523–9.
- Sontheimer RD. Perivascular dendritic macrophages as immunobiological constituents of the human dermal microvascular unit. *J Invest Dermatol* 1989;93:965–1015.
- Brandão AAH, Araujo NS, de Brito T, et al. FXIII+ dendritic cells in oral lesions of paracoccidioidomycosis [abstract E-37]. In: *Abstracts of the seventh international meeting on paracoccidioidomycosis*, Campos do Jordão, SP, Brazil, 1999.
- Pagliari C, Sotto MN. Correlation of factor XIIIa+ dermal dendrocytes with paracoccidioidomycosis skin lesions. *Med Mycol* 2002;40:407–10.
- Narvaez D, Kanitakis J, Faure M, et al. Immunohistochemical study of CD34 positive dendritic cells of human dermis. *Am J Dermatopathol* 1996;18:283–8.
- Nestle FO, Zheng XG, Thompson CB, et al. Characterization of dermal dendritic cells obtained from normal human skin reveals phenotypic and functionally distinctive subsets. *J Immunol* 1993;151:6535–45.
- Peters JH, Gieseler R, Thiel B, et al. Dendritic cells: from ontogenetic orphans to myelomonocytic descendants. *Immunol Today* 1996;17:273–7.
- Cano LE, Singer-Vermes LM, Vaz CAC, et al. Pulmonary paracoccidioidomycosis in resistant and susceptible mice: relationship among progression of infection, bronchoalveolar cell activation, cellular immune response and specific isotype patterns. *Infect Immun* 1995;63:1777–83.
- Musatti CC, Reskallah MT, Mendes E, et al. In vivo and in vitro evaluation of cell-mediated immunity in patients with paracoccidioidomycosis. *Cell Immunol* 1976;24:365–78.
- Benard G, Romano CC, Cacere CR, et al. Imbalance of IL-2, IFN- γ and IL-10 secretion in the immunosuppression associated with human paracoccidioidomycosis. *Cytokine* 2001;13:248–52.
- Diniz SN, Cisalpino PS, Freire ATF, et al. *In vitro* granuloma formation NO production and cytokines profile from human mononuclear cells induced by fractionated antigens of *Paracoccidioides brasiliensis*. *Hum Immunol* 2001;62:799–808.
- Mello LM, Silva-Vergara ML, Rodrigues V, Jr. Patients with active infection with *Paracoccidioides brasiliensis* present a Th2 immune response characterized by high interleukin-4 and interleukin-5 production. *Hum Immunol* 2001;63:149–54.
- Fornari MC, Bava AJ, Guereño MT, et al. High serum interleukin-10 and tumor necrosis factor alpha levels in chronic paracoccidioidomycosis. *Clin Diag Lab Immunol* 2001;8:1036–8.
- Oliveira SJ, Mamoni RL, Musatti CC, et al. Cytokines and lymphocyte proliferation in juvenile and adult forms of paracoccidioidomycosis: comparison with infected and non-infected controls. *Microbes Infect* 2002;4:139–44.
- Adams DO. The granulomatous inflammatory response. *Am J Pathol* 1976;84:164–91.
- Brito T, Franco MF. Granulomatous inflammation. *Rev Inst Med Trop São Paulo* 1994;36:185–92.
- Erber WN, Willis JI, Hoffman GJ. An enhanced immunocytochemical method for staining bone marrow trephine sections. *J Clin Pathol* 1997;50:389–93.
- Bieber T, Ring J, Braun-Falco O. Comparison of different methods for enumeration of Langerhans cells in vertical cryosections of human skin. *Br J Dermatol* 1988;118:385–92.
- Engwerda CR, Kaye PM. Organ-specific immune responses associated with infectious disease. *Immunol Today* 2000;21:73–8.
- Bos JD, Kapsenberg ML. The skin immune system. *Immunol Today* 1986;7:235–40.
- Franco M, Montenegro MR, Mendes RP, et al. Paracoccidioidomycosis: a recently proposed classification of its clinical forms. *Rev Soc Bras Med Trop* 1987;20:129–32.
- Mathur NK, Mangal HN, Mathur DC. Epidermal Langerhans cells in subtypes of leprosy. *Int J Lepr* 1984;52:92–3.
- Murphy GF, Messadi D, Fonferko E, et al. Phenotypic transformation of macrophages to Langerhans cells in the skin. *Am J Pathol* 1986;123:401–6.
- Tapia FJ, Caceres-Dittmar G, Acuna L, et al. Epidermal Langerhans cells in infectious diseases. *Histol Histopathol* 1989;4:499–508.
- Sandoval MP, Brito T, Sotto MN, et al. Antigen distribution in mucocutaneous biopsies of human paracoccidioidomycosis. *Int J Surg Pathol* 1996;3:181–8.
- Fina L, Molgaard HV, Robertson D, et al. Expression of the CD34 gene in vascular endothelial cells. *Blood* 1990;75:2417–26.
- Kashino SS, Fazioli RA, Cafalli-Favati C, et al. Resistance to *Paracoccidioides brasiliensis* infection is linked to a preferential Th1 immune response, whereas susceptibility is associated with absence of IFN- γ production. *J Interferon Cytokine Res* 2000;20:89–97.
- Souto JT, Figueiredo F, Furlanetto A, et al. Interferon- γ and tumor necrosis factor- α determine resistance to *Paracoccidioides brasiliensis* infection in mice. *Am J Pathol* 2000;156:1811–20.
- Heinzel FP, Sadick MD, Holaday BJ, et al. Reciprocal expression of interferon-gamma or interleukin 4 during the resolution or progression of murine leishmaniasis. Evidence for expansion of distinct helper T cell subsets. *J Exp Med* 1989;169:59–72.
- Yamamura M, Uyemura K, Deans RJ, et al. Defining protective responses to pathogens: cytokine profiles in leprosy lesions. *Science* 1991;254:277–9.
- Calich VLG, Vaz CAC, Burger E. Immunity to *Paracoccidioides brasiliensis* infection. *Res Immunol* 1998;149:407–17.
- Nestle FO, Turka L, Nickoloff BJ. Characterization of dermal dendritic cells in psoriasis. Autostimulation of T lymphocytes and induction of TH1 type cytokines. *J Clin Invest* 1994;94:202–9.
- Almeida SR, Lopes JD. The low efficiency of dendritic cells and macrophages from mice susceptible to *Paracoccidioides brasiliensis* in inducing a Th1 response. *Braz J Med Biol Res* 2001;34:529–37.
- Kalinski P, Hilken CMU, Wierenga EA, et al. T-cell priming by type-1 and type-2 polarized dendritic cells: the concept of a third signal. *Immunol Today* 1999;20:561–7.