

# Antigen distribution and antigen-presenting cells in skin biopsies of human chromoblastomycosis

**Background:** Chromoblastomycosis is a chronic, suppurative, granulomatous mycosis usually confined to skin and subcutaneous tissues. The host defense mechanisms in chromoblastomycosis have not been extensively investigated. The purpose of the present study was to determine the distribution and pathways of the fungal antigen(s) and the possible role of the different immunocompetent cells in antigen processing in skin lesions.

**Methods:** The distribution of *Fonsecaea pedrosoi* antigen(s) in human skin was studied in 18 biopsies from 14 patients with chromoblastomycosis. A purified polyclonal immune serum raised in rabbits against metabolic antigen(s) of *F. pedrosoi* was used to detect yeast antigen(s) by immunohistochemical procedures. Double immunolabeling was performed with yeast antigen(s) and Langerhans' cells [labeled with anti-S100 protein monoclonal antibody (MoAb)], yeast antigen(s) and factor XIIIa<sup>+</sup> dermal dendrocytes (immunolabeled with anti-factor XIIIa polyclonal antibody), and yeast antigen(s) and macrophages (labeled with CD 68 monoclonal antibody).

**Results:** The *F. pedrosoi* antigen(s) accumulated in the skin macrophages and, in a few instances, in factor XIIIa<sup>+</sup> dendrocytes and Langerhans' cells.

**Conclusions:** The data obtained suggest that chiefly macrophages, also Langerhans' cells and factor XIIIa<sup>+</sup> dermal dendrocytes, function as antigen-presenting cells in chromoblastomycosis.

Sotto MN, De Brito T, Silva AMG, Vidal M, Castro LGM. Antigen distribution and antigen-presenting cells in skin biopsies of human chromoblastomycosis.

J Cutan Pathol 2004; 31: 14–18. © Blackwell Munksgaard 2004.

Mírian N. Sotto<sup>1,2</sup>, T. De Brito<sup>2</sup>,  
Ana Maria G. Silva<sup>2</sup>, Monica  
Vidal<sup>2</sup> and L. G. Martins Castro<sup>1</sup>

<sup>1</sup>Department of Dermatology, and

<sup>2</sup>Institute of Tropical Medicine, University of São Paulo Medical School, Sao Paulo, Brazil

Mírian N. Sotto, MD, Instituto de Medicina Tropical de Sao Paulo, Av. Dr Enéas de Carvalho Aguiar 470, CEP 05403 – 000, Sao Paulo, Brazil

Tel: +55-11-3066-7066

Fax: +55-11-3063-0718

e-mail: mnsotto@ajato.com.br

Accepted August 6, 2003

Chromoblastomycosis is a chronic, suppurative, granulomatous mycosis of the skin and subcutaneous tissues, which usually shows no major tendency to disseminate to deeper organs. It occurs worldwide, but it is more frequently observed in tropical countries. This mycosis is caused by several species of pigmented hyphomycetes fungi known as dematiaceous fungi, chiefly *Fonsecaea pedrosoi*, and, to a lesser extent, by species such as *Phialophora verrucosa* amongst others.<sup>1</sup> This group of closely related black fungi varies in their microscopic appearance in culture but have only a single tissue form, the sclerotic cell. The

histologic feature is characterized by a suppurative granulomatous dermatitis, usually combined with pseudocarcinomatous hyperplasia of epidermis and variable dermal fibrosis in skin. The fungi are seen in the center of micro abscesses and within multinucleated giant cells.<sup>2–6</sup>

The host defense mechanisms in chromoblastomycosis have not been extensively investigated. Precipitating antibodies have been detected, in several studies, in patients with this disease<sup>7</sup>, but the role of humoral factors in the host defense mechanisms against dematiaceous fungi remain unclear. The

cell-mediated immune response is also present in chromoblastomycosis<sup>8,9</sup> and has histological expression in the granulomatous response of the host.

The purpose of the present study was to determine the distribution and pathways of the antigen(s) in the skin of patients with chromoblastomycosis and the possible role of the different immunocompetent cells in antigen processing.

**Materials and methods**

Fourteen patients were examined in the Department of Dermatology, Sao Paulo University Medical School, where 18 surgical biopsies were taken for diagnostic purposes. All patients exhibited the typical verrucous, ulcerated crusted lesions. The diagnosis, made by observation of thick-walled septate pigmented fungi, was confirmed by culture and histological examination. The main clinical and culture data are presented in Table 1.

The polyclonal immune serum used in the immuno histochemical (IHC) reactions was raised in rabbits against a metabolic antigen of *F. pedrosoi* according to a standard protocol.<sup>7</sup> The metabolic antigen was obtained from culture 884 of *F. pedrosoi* (Laboratory of Mycology, Institute of Tropical Medicine, São Paulo University Medical School) in Sabouraud-dextrose at 25°C for 30 days. The culture was filtered through number 1 Whatman paper, and the resulting filtrate was concentrated 10 times and used as an antigen. In a previous study, Vidal<sup>7</sup> standardized routine serologic reactions such as double immunodiffusion, counterimmunoelectrophoresis, immunoglobulin G-enzyme-linked immunosorbent assay, and immunoblotting for the evaluation of serum samples from chromoblastomycosis patients (etiologic agent, *F. pedrosoi*). Also, electrophoretic analysis of the

antigen(s) (SDS-PAGE) was performed as well as analysis of sensitivity and specificity of the reactions. Controls included sera from sporotrichosis and cutaneous leishmaniasis patients and from normal individuals.

A positive immunoreactivity of fungal cell walls for factor XIIIa has been described<sup>11</sup>, and in order to block this immunostaining, a purification of the anti-factor XIIIa antibody was performed. *F. pedrosoi* was cultured at 25°C for 10 days in Sabouraud medium containing chloramphenicol (100 mL). The cultures were then killed with formalin for 3 days at 4°C. After centrifugation, the supernatant was removed and the resulting sediment of yeast cells (83 mg) was incubated for 24 h at 5°C in 1000 µL of the anti-factor XIIIa antibody (Calbiochem, La Jolla, CA, USA) at 1 : 50 dilution.

Tissue blocks were chosen for IHC analysis after a review of hematoxylin and eosin-stained skin specimens. Sections that were 4–5 µm thick were mounted onto 3-aminopropyltriethoxysilane-coated glass slides, dried at 37°C and stored at 60°C for at least 48 h prior to use. Before staining, sections were routinely deparaffinized and rehydrated through graded alcohols and distilled water.

The avidin–biotin–horseradish peroxidase (DAKO, K0492, Copenhagen, Denmark) complex detection system was employed to detect antibody–antigen binding using 3,3'-diaminobenzidine tetrahydrochloride (DAB) (SIGMA, D-5637, St. Louis, MO, USA) as the chromogen. EnVision (DAKO Laboratory K-4017, Carpinteria, CA, USA) was also applied according to manufacturer instructions which included the use of New Fuchsin (Biogenex HK 183–5K, San Ramon, CA, USA) and NBT/BCIP alkaline phosphatase (SIGMA B 5655) for development.

Table 1. Clinical data of 14 patients with chromoblastomycosis

Patient	Gender	Age (years)	Lesion	Site of lesion	Agent	Severity <sup>†</sup>	Disease duration (years)	Therapy <sup>*</sup>
1	M	72	Verrucous plaque	Right lower limb	<i>Fonsecaea pedrosoi</i>	Moderate	10	LN + ITZ
2	M	42	Verrucous and ulcerated plaque	Right lower limb	<i>F. pedrosoi</i>	Moderate	10	WT
3*	M	54	Verrucous plaque	Right lower limb	<i>F. pedrosoi</i>	Minor	04	WT
4*	M	55	Verrucous plaque	Right upper limb	<i>F. pedrosoi</i>	Moderate	08	WT, LN + ITZ
5	M	87	Verrucous plaque	Left upper limb	<i>F. pedrosoi</i>	Moderate	09	WT
6	M	55	Verrucous plaque	Right upper limb	<i>F. pedrosoi</i>	Minor	01	WT
7	M	48	Verrucous plaque	Left buttock	<i>F. pedrosoi</i>	Moderate	10	WT
8	M	53	Verrucous plaque	Left lower limb	NR	Severe	10	WT
9	M	81	Verrucous and ulcerated plaque	Right lower limb	<i>F. pedrosoi</i>	Moderate	45	WT
10	F	64	Multiple nodules	Right lower limb	<i>F. pedrosoi</i>	Severe	02	WT
11*	F	36	Verrucous plaque	Left lower limb	<i>F. pedrosoi</i>	Minor	04	LN
12	M	39	Lichenified plaque	Left lower limb	NR	Minor	01	WT
13*	M	71	Verrucous and ulcerated plaque and nodules	Right lower limb	NR	Moderate	20	ITZ
14	M	51	Verrucous plaque	Right lower limb	<i>F. pedrosoi</i>	Minor	NR	NR

ITZ, oral itraconazole; LN, cryosurgery with liquid nitrogen; NR, not recorded; WT, without therapy at the time of biopsy.

\*Two biopsies studied.

<sup>†</sup>Disease severity according to Castro et al., 2003.<sup>10</sup>

<sup>\*</sup>Ongoing therapy at the time of biopsy.

Double staining was performed in order to detect fungal antigen(s) and/or the fungus itself internalized in macrophages, Langerhans' cells, and factor XIIIa<sup>+</sup> dendrocytes (FXIIIa<sup>+</sup> DD). Optimal conditions for primary antibodies and digestion conditions were previously determined by titration experiments. Slides were initially submitted to trypsin digestion (20 mg/100 mL, 134 mg of calcium chloride in 100 mL of phosphate buffer saline, pH 7.8) for 15 min. Endogenous peroxidase activity was quenched by incubating sections for 20 min in a 50:50 6% peroxidase and methanol solution. The anti-*F. pedrosoi* immune serum was applied at 1:30,000 dilution overnight at 4°C, after being previously adsorbed with 30 mg of normal human skin acetone powder.<sup>12</sup> After 6% defatted milk blockade, S100 protein antibody (DAKO A/S, Z0311, Denmark) was applied for 1 h at 37°C at 1:800 dilution followed by streptavidin–biotin–horseradish peroxidase (DAKO, Denmark, Strept AB complex/HRP Duet, Mouse/Rabbit) diluted at 1:1000 at 37°C. The reaction was developed with DAB (50 mg) and nickel (40 mg) for 4 min. The anti-*F. pedrosoi* immune serum was also used at 1:8000 dilution followed by EnVision peroxidase and developed with DAB (50 mg) and nickel (40 mg). S100 was applied at 1:800 dilution followed by EnVision alkaline phosphatase (AP) and developed with new fuchsin.

In order to demonstrate FXIIIa<sup>+</sup> DD, deparaffinized slides, after incubation with anti-*F. pedrosoi* serum, as described above, were incubated with purified anti-factor XIIIa antibody diluted at 1:200 for 1 h at 37°C. Macrophages were demonstrated with anti-CD68 monoclonal antibody (DAKO A/S, M0814, Denmark) at 1:800 dilution also for 1 h at 37°C. EnVision was then applied in both instances and developed with new Fuchsin (Biogenex, code HR 183–5k, San Ramon, CA, USA). Slides were counterstained by either hematoxylin or methyl green.

Positive controls were slides of a human cerebral abscess due to *F. pedrosoi* rich in fungi. Negative controls were as follows: 1) omission of the primary antibodies which were replaced with normal rabbit serum,<sup>2</sup> 2) the anti-*F. pedrosoi* immune serum was applied to tissue sections of normal human skin, biopsies of sporotrichosis, paracoccidiomycosis, and visceral and cutaneous leishmaniasis with negative results.

## Results

### Histopathological findings

The microscopic findings were essentially similar in all biopsies studied, with quantitative differences in epidermal reactive processes and in dermal collagen and yeast concentration. The epidermis showed hyperkeratosis with parakeratosis, acanthosis, pseudo-carcinomatous hyperplasia, and papillomatosis.

Intraepidermal keratolytic abscesses were frequently observed with or without yeast cells alone or in clusters. Fungi were observed isolated between keratinocytes, probably during the so-called transepithelial migration and were rarely found in the horny layer. In this last instance, dematiaceous hyphae could be observed. The dermis contained a dense inflammatory infiltrate dominated by neutrophils, occasionally forming intradermal abscesses and macrophages. Eosinophils, lymphocytes, plasma cells, and mast cells were present. Both epithelioid and poorly organized granulomas made up of aggregates of macrophages and epithelioid cells, frequently with a suppurative center, could be observed with giant cells of the Langhans and/or foreign body type. Yeast forms were detected in the center of the granuloma, occasionally in the cytoplasm of giant cells (Fig 1A). Cicatricial fibrosis was frequent, and the fibrotic reaction usually extended from the superficial to the lower dermis, obliterating skin adnexa, and, in few cases, predominating over the active inflammatory reaction described.

### Antigen demonstration

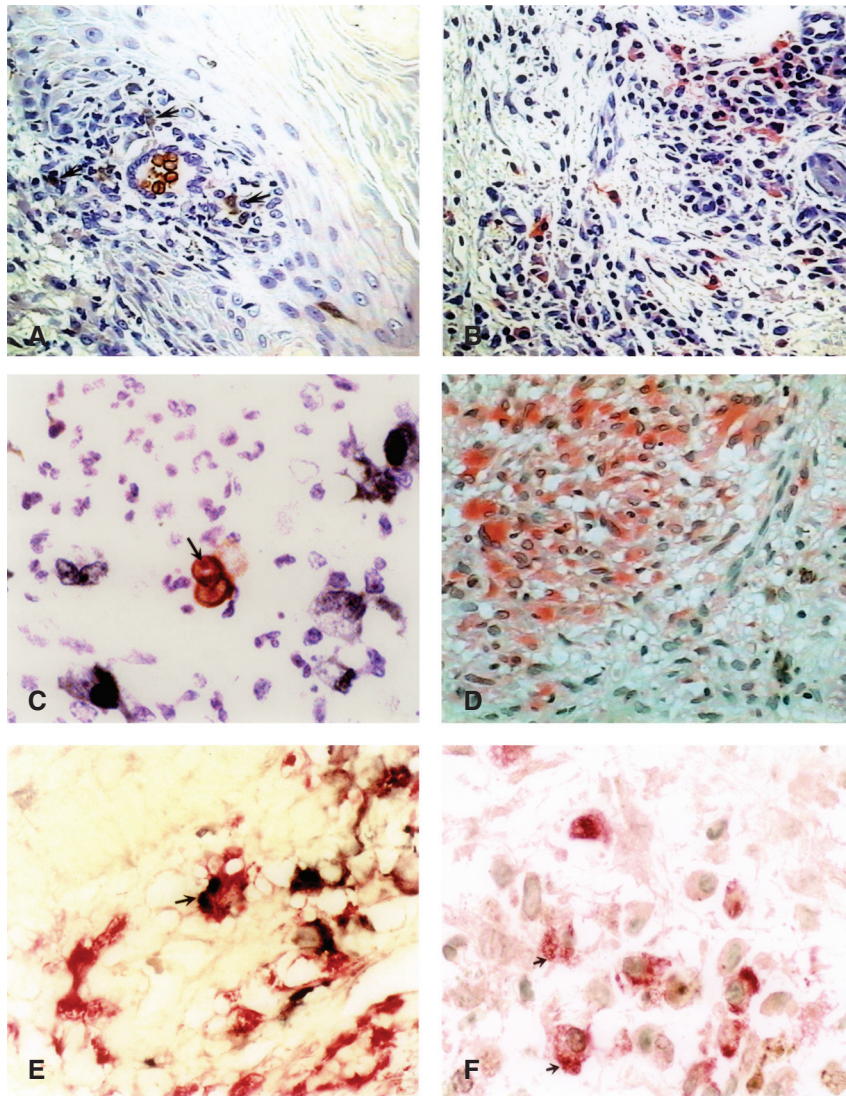
Yeast antigen(s) were demonstrated by the polyclonal antiserum in the cytoplasm of macrophages in the dermal inflammation in all biopsies. The fungal antigenic material was revealed by different chromogens as homogenous material within the macrophage cytoplasm. The detection of antigen(s) in the fungal cell had an unfavorable bias represented by its brownish color. However, when nitroblue tetrazolium or DAB nickel enhancement was used as the label, there were prominent deposits of the products of the reaction over the fungus cell wall. Antigen(s) were detected as dots or rings in the cytoplasm of the yeast cell (Fig 1C). Epithelioid and giant cells of the granuloma did not exhibit positive staining for fungal antigen.

### Double-staining technique

In five biopsies, isolated FXIIIa<sup>+</sup> DD exhibited immune labeling to fungal antigen that appeared as homogenous deposits within their cytoplasm (Fig 1E). These cells, however, appeared in large numbers, chiefly in the dermal papillae, hypertrophied with prominent dendrites in all patients (Fig 1D), except in few cases where cicatricial fibrosis was more accentuated. Langerhans' cells labeled with S100 protein antibody were prominent in the epidermis and were seen in superficial dermis sometimes close to and/or admixed with monocytes and epithelioid cells of the granulomatous inflammation (Fig 1A). Granular deposits of yeast antigen(s) were occasionally observed in the



## Antigen distribution in chromoblastomycosis



**Fig. 1.** A) A poorly organized granuloma is present in the papillary dermis with a Langhans' giant cell with typical fungi in the cytoplasm. Langerhans' cells (stained in black by anti-S100 protein antibody) are seen in the epidermis and admixed with macrophages and elongated cells, probably epithelioid cells of the granuloma (arrows). Double-labeling technique EnVision System (Dako Corporation, Carpinteria, USA) ( $\times 400$ ). B) Dense inflammatory infiltrate in the dermis, made up of lymphocytes, plasma cells, and macrophages that exhibit chromoblastomycosis antigen as homogenous material (stained in red) in the cytoplasm. Anti-*Fonsecaea pedrosoi*, EnVision AP, New fuchsin ( $\times 400$ ). C) Anti-*F. pedrosoi* antibody stains cellular membrane and cytoplasmic antigen as dots in a yeast form (arrow) observed amongst cellular debris (EnVision AP, New fuchsin) ( $\times 600$ ). D) Proliferated and hypertrophied factor XIIIa<sup>+</sup> dermal dendrocytes are seen in the dermis (stained in red). Anti-factor XIIIa antibody (EnVision AP, New fuchsin) ( $\times 400$ ). E) Double-labeling technique showing the presence of fungal antigen(s) (stained deep blue) in the cytoplasm of factor XIIIa<sup>+</sup> dermal dendrocytes (stained in red arrow) in the dermis. Double stain EnVision System ( $\times 600$ ). F) Double-labeling technique showing Langerhans' cells in the dermis (S100-positive cells stained in deep red) with light-brown granules of fungal antigen(s) in the cytoplasm revealed by anti-*F. pedrosoi* antibody. Double stain EnVision System ( $\times 600$ ).

cytoplasm of Langerhans' cells in the dermis in 3 out of 18 biopsies (Fig 1F).

### Discussion

The main histopathological findings were essentially similar to those previously described.<sup>1-6</sup> The morphology and color of the fungus are usually sufficiently characteristic to establish the diagnosis, and biopsies are performed for this purpose. The fungus is

commonly present as yeast cells in the cutaneous lesions, but favorable factors seldom induce hyphal morphogenesis. In our patients, this was observed in the epidermal keratotic layer.

Few studies address the host-parasite relationship in cutaneous chromoblastomycosis. Antibodies have been detected in such patients,<sup>7</sup> and the cell-mediated response has been investigated in two studies.<sup>8,9</sup> There are few studies evaluating the immunophenotype of the cellular elements related to cell-mediated

immunity in the inflammatory response in chromoblastomycosis skin lesions. It is composed of T lymphocytes (both CD4<sup>+</sup> and CD8<sup>+</sup>), B lymphocytes, and numerous macrophages.<sup>5,13</sup> We demonstrated that the *F. pedrosoi* antigen(s) are observed mainly in the macrophage cytoplasm as homogenous or granular material. Ultrastructural studies<sup>14</sup> showed that, in the skin, the organisms are found in macrophages in large limited intracytoplasmic vacuoles. The *in situ* persistence of the fungi and the consequent continuous antigenic stimuli are probably factors contributing to the disorganized matrix pattern and the extensive and progressive dermal fibrosis.<sup>5,6,15</sup> Antigen(s) were also observed in the cytoplasm of proliferated and hypertrophic FXIIIa<sup>+</sup> DD. Similar to paracoccidioidomycosis<sup>11,16</sup> both probably function as antigen-presenting cells (APCs) in chromoblastomycosis. Langerhans' cells in the dermis appeared to be conspicuous and occasionally were part of the granulomatous inflammation. Rarely, they showed homogenous material or granules of yeast antigen(s) in the cytoplasm. Possibly, as APCs, either they require less or different antigen(s) than the ones detected by our immunohistochemical techniques or play a secondary role in the immunology of chromoblastomycosis infection. Dendritic cells in the skin comprise a large family of leukocytes with related morphology, with a unique ability to induce primary immune responses. Unlike other APCs such as macrophages or B cells, dendritic cells, when activated, are thought to have also the function to regulate T responses and B responses. Dendritic cells may also be important for the induction of immunological tolerance as well as for the regulation of the type of T-cell-mediated immune response.<sup>17,18</sup> Amongst the dendrocytes of the skin, there is a group distinguished by the expression of coagulation factor XIIIa in their cytoplasm and the absence of positivity for S100 protein and antigens expressed by macrophages and fibroblasts. Such dendrocytes are frequent in the skin, originate in bone marrow and are important APCs in paracoccidioidomycosis.<sup>11</sup> In chromoblastomycosis, such dendrocytes as well as Langerhans' cells appeared to be prominent but the detection of antigen(s) in their cytoplasm was infrequent with the immunohistochemical procedure employed. However, it must be remembered that dendrocytes are thought to have other functions, also important during inflammation such as regulation of T responses and B responses, and their activation, as seen in chromoblastomycosis, can trigger production of cytokines, which can polarize emerging T-cell responses.<sup>18</sup>

## Acknowledgements

Financial support for this project was provided by CNPq (300857/94 – 2 – NV), LIM-HCFMUSP 06 and 53.

## References

1. Bonifaz A, Carrasco-Gerard E, Saúl A. Chromoblastomycosis: clinical and mycologic experience of 51 cases. *Mycoses* 2002; 44: 1.
2. Emmons CW, Binford CH, Utz JP. Chromomycosis. In: Emmons CW, Binford CH, Utz JP, eds. *Medical Mycology*. Philadelphia: Lea & Febiger, 1970, 386.
3. Chandler FW, Kaplan W, Ajello L. Chromoblastomycosis. In: Chandler FW, Kaplan W, Ajello L, eds. *A colour atlas and textbook of the histopathology of mycotic diseases*. London: Wolfe Medical Publications, 1980, 47.
4. Uribe JF, Zuluaga AI, Leon W, Restrepo A. Histopathology of chromoblastomycosis. *Mycopathologia* 1989; 105: 1.
5. Esterre P, Ravisse P, Peyrol S, et al. Immunopathologie de la lésion cutanée de chromomycose. *J Mycol Méd* 1991; 1: 201.
6. Esterre P, Peyrol S, Guerret S, Sainte-Marie D, Pradinaud R, Grimaud JA. Cell-matrix patterns in the cutaneous lesion of chromomycosis. *Pathol Res Pract* 1992; 188: 894.
7. Vidal MSM. Immunochemical study of *Fonsecaea pedrosoi* antigens and standardization of serological techniques for chromoblastomycosis. *Rev Inst Med Trop Sao Paulo* 2002; 44: 238.
8. Iwatsu T, Miyagi M, Taguchi H, Okamoto S, Kurita W. Skin test-active substance prepared from culture filtrate of *Fonsecaea pedrosoi*. *Mycopathologia* 1979; 67: 101.
9. Kurita N. Cell mediated immune responses in mice infected with *Fonsecaea pedrosoi*. *Mycopathologia* 1979; 68: 9.
10. Castro LGM, Pimentel ERA, Lacaz CS. Treatment of chromomycosis by cryosurgery with liquid nitrogen: 15 years' experience. *Int J Dermatol* 2003; 42: 408.
11. Pagliari C, Sotto MN. Correlation of factor XIIIa<sup>+</sup> dermal dendrocytes with paracoccidioidomycosis skin lesions. *Med Mycol* 2002; 40: 407.
12. Sotto MN, Yamashiro-Kanashiro E, Matta VLR, de Brito T. Cutaneous leishmaniasis of the New World: diagnostic immunopathology and antigen pathways in skin and mucosa. *Acta Trop* 1989; 46: 121.
13. D'Avila SC, Pagliari C, Duarte MI. The cell-mediated immune reactions in the cutaneous lesion of chromoblastomycosis and their correlation with different clinical forms of the disease. *Mycopathologia* 2003; 156: 51.
14. Walter P, Garin Y, Richard-Lenoble D. Chromoblastomycosis: a morphological investigation of the host-parasite interaction. *Virchows Arch A Pathol Anat Histopathol* 1982; 397: 203.
15. Esterre P, Peyrol S, Sainte-Marie D, Pradinaud R, Grimaud JA. Granulomatous reaction and tissue remodelling in the cutaneous lesion of chromomycosis. *Virchows Arch A Pathol Anat Histopathol* 1993; 422: 285.
16. Sandoval M, De Brito T, Sotto MN, Santos RT, Franco MF. Antigen distribution in mucocutaneous biopsies of human paracoccidioidomycosis. *Int J Surg Pathol* 1996; 3: 181.
17. Banchereau J, Briere F, Caux C, et al. Immunobiology of dendritic cells. *Annu Rev Immunol* 2000; 18: 767.
18. Reis e Sousa C. Minireview: dendritic cells as sensors of infection. *Immunity* 2001; 14: 495.